

# ARCUATE UTERUS IDENTIFIED ON PELVIC MRI: A NORMAL VARIANT MIMICKING SEPTATE UTERUS

Mitreska J.A.<sup>1,2</sup>, Nedev S.<sup>1,2</sup>, Nikolova S.<sup>1,2</sup>

<sup>1</sup>*Institute of Radiology, Skopje, Republic of North Macedonia*

<sup>2</sup>*Faculty of Medicine, Ss. Cyril and Methodius University, Skopje, Republic of North Macedonia*

## Abstract

**Background:** Accurate differentiation of Müllerian duct anomalies is a critical component of infertility assessment. A septate uterus is associated with adverse reproductive outcomes and often requires surgical correction, whereas an arcuate uterus is considered a benign anatomical variant with no proven clinical significance. Magnetic resonance imaging (MRI) offers superior characterization of uterine morphology, enabling precise diagnosis.

**Case Presentation:** A 35-year-old woman undergoing infertility evaluation was referred for pelvic MRI due to a suspected septate uterus. MRI demonstrated a normal external uterine fundal contour with a smooth, broad concave indentation of the endometrial fundus measuring less than 1 cm. No fibrous septum or cavity division was identified, findings consistent with an arcuate uterus. Both ovaries were normal, and a small amount of physiologic pelvic free fluid was present.

**Conclusion:** This case underscores the pivotal role of MRI in distinguishing an arcuate uterus from a septate uterus during infertility work-up. Accurate imaging diagnosis prevents unnecessary surgical intervention and allows appropriate reproductive counseling.

**Keywords:** *Arcuate uterus; Infertility; Müllerian duct anomalies; Pelvic MRI; Septate uterus*

## Introduction

Müllerian duct anomalies (MDAs) comprise a heterogeneous group of congenital uterine malformations resulting from abnormal development, fusion, or resorption of the paramesonephric ducts during embryogenesis. These anomalies may alter uterine morphology and are clinically relevant in the context of infertility, recurrent pregnancy loss, dysmenorrhea, and adverse obstetric outcomes. Precise classification is essential, as management and prognosis vary substantially among different anomaly types. However, overlapping morphologic features often complicate diagnosis, particularly when imaging fails to adequately assess both the endometrial cavity and the external uterine contour (1).

The arcuate uterus represents a mild deviation within the spectrum of normal uterine anatomy rather than a true congenital malformation. It is characterized by a shallow, broad concavity of the endometrial fundal surface caused by minimal midline septal resorption failure. Unlike septate or bicornuate uteri, the arcuate uterus preserves a normal external fundal contour and has not been consistently associated with impaired fertility or adverse pregnancy outcomes. Never-

theless, its subtle appearance may mimic a partial septum, particularly on suboptimal imaging planes or limited modalities, leading to frequent misclassification and overtreatment (2,3).

Pelvic MRI is widely regarded as the reference standard for evaluation of MDAs owing to its excellent soft-tissue contrast, multiplanar capability, and reproducibility. Crucially, MRI allows simultaneous assessment of both the internal uterine cavity and the external serosal contour, a cornerstone of modern classification systems, including the ASRM 2021 and ESHRE/ESGE frameworks. In an arcuate uterus, MRI typically demonstrates a smooth fundal indentation measuring less than 1 cm with an otherwise normal convex or flat external contour—features that reliably differentiate it from a septate uterus, in which a fibrous or fibromuscular septum extends  $\geq 1$  cm toward the uterine cavity (4–6).

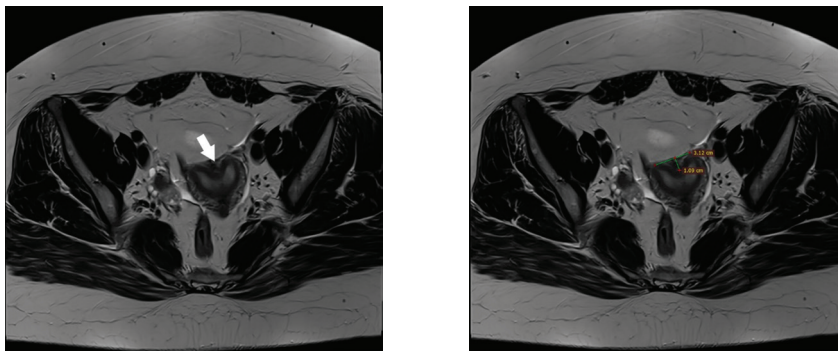
With the increasing use of MRI in infertility evaluation, recognition of the arcuate uterus as a benign variant is essential to avoid misdiagnosis and unnecessary surgical intervention. This case report illustrates the MRI appearance of an arcuate uterus initially suspected to be septate, highlighting key diagnostic features and emphasizing the importance of accurate morphologic interpretation.

## Case Presentation

A 35-year-old woman was referred for pelvic MRI following ultrasound suspicion of a septate uterus during infertility evaluation. She reported no history of recurrent pregnancy loss, dysmenorrhea, or other gynecologic symptoms. MRI was performed using standard pelvic protocols, with high-resolution T2-weighted sequences in axial, sagittal, and coronal planes, without intravenous contrast.

## Imaging Findings

MRI demonstrated a normal uterine size and configuration with a preserved external fundal contour. A smooth, broad concave indentation of the endometrial fundus measuring less than 1 cm in depth was identified. No fibrous septum, muscular ridge, or division of the uterine cavity was present. The uterine cavity appeared single and undistorted. Both ovaries were normal in size and morphology, containing multiple age-appropriate follicles. A small amount of physiologic free fluid was noted in the rectouterine pouch.



**Figure 1 a) and b).** Axial T2-weighted pelvic MRI images (a, b) demonstrate a smooth, broad concave indentation of the endometrial fundus measuring less than 1 cm in depth (white arrow), with preservation of the external uterine contour. No fibrous or muscular septum is identified, consistent with an arcuate uterus.

---

## Discussion

Although the arcuate uterus is now widely accepted as a normal anatomical variant, it remains a frequent source of diagnostic ambiguity. Earlier classification systems, including the original 1988 ASRM framework, categorized an arcuate uterus as a mild resorption defect. Contemporary consensus, reflected in the ASRM 2021 update, recognizes it as a benign variant without demonstrable impact on fertility or pregnancy outcomes (1,5). Accurate differentiation from a septate uterus is critical, as the latter is associated with increased risk of miscarriage and may warrant hysteroscopic septum resection.

Diagnostic challenges arise particularly when imaging techniques inadequately visualize the uterine fundal contour. Two-dimensional ultrasound, although widely available, is limited by operator dependence and by its restricted evaluation of the external uterine surface. Three-dimensional ultrasound improves diagnostic accuracy but remains less accessible and susceptible to technical limitations. MRI, therefore, serves as a decisive problem-solving modality, offering reproducible, high-resolution assessment of both internal cavity morphology and serosal contour (3,6).

In an arcuate uterus, MRI consistently demonstrates a shallow, broad endometrial indentation measuring less than 1 cm in the absence of an external fundal cleft. In contrast, a septate uterus is defined by a fibrous or fibromuscular septum extending  $\geq 1$  cm into the uterine cavity, with preservation of the external contour. Applying these criteria helps prevent misclassification, as repeatedly highlighted in radiologic and gynecologic literature, and avoids unnecessary hysteroscopic intervention, thereby reducing avoidable anesthetic and perioperative risk (2,7).

The ESHRE/ESGE classification, while valuable for standardization, has been criticized for its increased sensitivity and potential overdiagnosis of a septate uterus when internal cavity measurements are emphasized without equal consideration of the external fundal contour. The ASRM 2021 classification addresses this limitation by reinstating indentation depth thresholds and explicitly defining arcuate uterus as a normal variant. MRI is uniquely suited to apply these criteria accurately, reinforcing its central role in equivocal cases.

The present case fulfills all ASRM 2021 criteria for arcuate uterus: a normal external uterine contour, an endometrial fundal indentation less than 1 cm, and absence of a true septum. Recognition of these features allowed confident exclusion of a septate uterus and avoidance of unnecessary intervention.

## Conclusion

An arcuate uterus represents a benign anatomical variant without established reproductive significance. Accurate distinction from a septate uterus is essential, particularly in infertility evaluation. MRI provides a reliable assessment of uterine morphology and fundal contour, enabling precise classification and preventing unnecessary surgical treatment and related anesthetic risk. Awareness of this normal variant is crucial for both radiologists and clinicians to ensure appropriate patient counseling and management.

Ethics approval and consent to participate: A formal approval of the Ethics Committee was not required for this study.

Consent for publication: Written informed consent was obtained from the patient prior to inclusion.

Conflict of interest: The authors report no financial or personal conflicts of interest.

Funding: This research received no external funding.

Authors' contributions: Conceptualization and study design: A.J.; Image acquisition and interpretation: S.N.; Literature review and analysis: A.J.; Manuscript drafting: A.J.; Critical revision of the manuscript for important intellectual content: S.N. All authors approved the final version of the manuscript and agree to be accountable for all aspects of the work.

Use of Artificial Intelligence (AI) tools: The authors declare that no artificial intelligence tools were used in the preparation of this manuscript.

Acknowledgments: The authors thank the radiology staff of the Institute of Radiology, Faculty of Medicine, Ss. Cyril and Methodius University in Skopje, for their technical support and assistance during image acquisition.

## References:

1. Chandler TM, Machan LS, Cooperberg PL, Harris AC, Chang SD. Müllerian duct anomalies: from diagnosis to intervention. *Br J Radiol.* 2009; 82:1034–1042.
2. Imaoka I, Wada A, Matsuo M, Yoshida M, Kitagaki H, Sugimura K. MR imaging of disorders associated with female infertility: use in diagnosis, treatment, and management. *Radiographics.* 2003; 23:1401–1421.
3. Santos Montón C, Martín Izquierdo M, Correa Soto RE, Alonso Diego I, Hernández Rodríguez C, Gallego García S. MR imaging of uterovaginal anomalies: what the surgeon needs to know before surgery. EPOS™ (ECR 2019). Poster No. C-0237. Available from: <https://epos.myesr.org/poster/esr/ecr2019/C-0237>
4. Pfeifer SM, Attaran M, Goldstein J, Lindheim SR, Petrozza JC, Rackow BW, et al. ASRM Müllerian anomalies classification 2021. *Fertil Steril.* 2021;116(5):1238–1252. doi: 10.1016/j.fertnstert.2021.09.025
5. Jegannathan D, Indiran V. Magnetic resonance imaging of classified and unclassified Müllerian duct anomalies: comparison of the American Society for Reproductive Medicine and the European Society of Human Reproduction and Embryology classifications. *SA J Radiol.* 2018;22(1):1259. doi:10.4102/sajr.v22i1.1259
6. Darwish OM, Mustafa AEM. Müllerian duct anomalies: diagnostic impact of magnetic resonance imaging. *J Med Sci Clin Res.* 2018;6(1):02. Available from: <https://dx.doi.org/10.18535/jmscr/v6i1.02>
7. Mahmud A. Arcuate uterus. *Radiopaedia.org.* Case study. Available from: <https://doi.org/10.53347/rID-73155>. Accessed December 16, 2025.