

CASE REPORT

INVASIVE DUCTAL CARCINOMA IN AN ELDERLY PATIENT: HOW SOCIOECONOMIC BARRIERS INFLUENCE DIAGNOSTIC DELAY AND TREATMENT PATHWAYS

Lukarov V.

¹*Institute of Radiology, Faculty of Medicine, Ss. Cyril and Methodius University, Skopje, Republic of North Macedonia*

²*Public Health Institution – General Hospital, Veles, Republic of North Macedonia*

Abstract

Invasive breast carcinoma is the most common malignant breast tumor and remains a major global public health challenge, with high morbidity and mortality rates among women worldwide. Early diagnosis relies on clinical assessment, imaging, and histopathological evaluation, while treatment requires a multidisciplinary approach. Invasive ductal carcinoma (IDC) accounts for approximately 70–80% of invasive cases, most frequently metastasizing to regional lymph nodes and distant organs via lymphatic and hematogenous pathways.

We present a case of a 78-year-old female with a palpable retro areolar mass in the right breast, accompanied by nipple retraction, erythema, and peau d'orange appearance. Imaging, including mammography, CT, and ultrasound, demonstrated an irregular, multilobulated, hypoechoic lesion consistent with malignancy, while fine-needle aspiration biopsy confirmed invasive ductal carcinoma. Immunohistochemistry revealed strong estrogen receptor positivity (ER 90%) and weak progesterone receptor expression (PR 2%), suggesting a hormonally driven tumor subtype with therapeutic implications.

This case highlights the diagnostic value of multimodal imaging and histopathology in elderly patients, where delayed presentation, comorbidities, and low socioeconomic status may complicate both the diagnostic process and access to timely treatment. It underscores the importance of early detection, sustained clinical suspicion, and a coordinated multidisciplinary approach to optimize outcomes in invasive breast carcinoma.

Keywords: *invasive ductal carcinoma; multimodal imaging; peau d'orange; ER positive breast cancer.*

Introduction

Invasive breast carcinoma remains one of the leading causes of cancer-related mortality among women worldwide, with a lifetime risk estimated at approximately one in eight women (1,2). It most commonly arises from epithelial cells of the ductal-lobular system and is characterized by stromal invasion and metastatic potential via lymphatic and hematogenous pathways (3,4). Histologically, invasive ductal carcinoma (IDC) comprises 70–80% of cases, while invasive lobular carcinoma accounts for 10–15% (3).

The biological behavior and treatment approach are strongly influenced by molecular subtype, particularly the expression of estrogen (ER), progesterone (PR), and HER2 receptors, which guide targeted therapy and correlate with prognosis (5). Established risk factors include genetic predisposition (BRCA1/2 mutations), hormonal influences, ionizing radiation, and lifestyle factors (5).

Clinical presentation varies from asymptomatic disease detected on screening to palpable masses, nipple changes, or “peau d’orange” appearance due to lymphatic obstruction. Definitive diagnosis requires histopathology supported by imaging modalities such as mammography, ultrasound, MRI, and CT (3,4).

Elderly patients often present with diagnostic challenges due to delayed clinical evaluation, comorbidities, and atypical or advanced disease at presentation, complicating staging and treatment decisions.

The aim of this case report is to present a case of a 78-year-old female patient with invasive ductal carcinoma, which emphasizes the role of multimodal imaging, pathological evaluation, and clinical considerations in elderly patients.

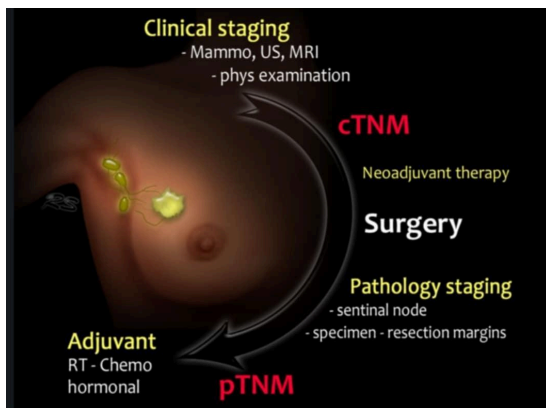


Figure 1. Clinical and pathological staging pathway in breast cancer, illustrating the diagnostic sequence from cTNM evaluation to surgery and pTNM classification, guiding adjuvant therapy (6).

Case Presentation

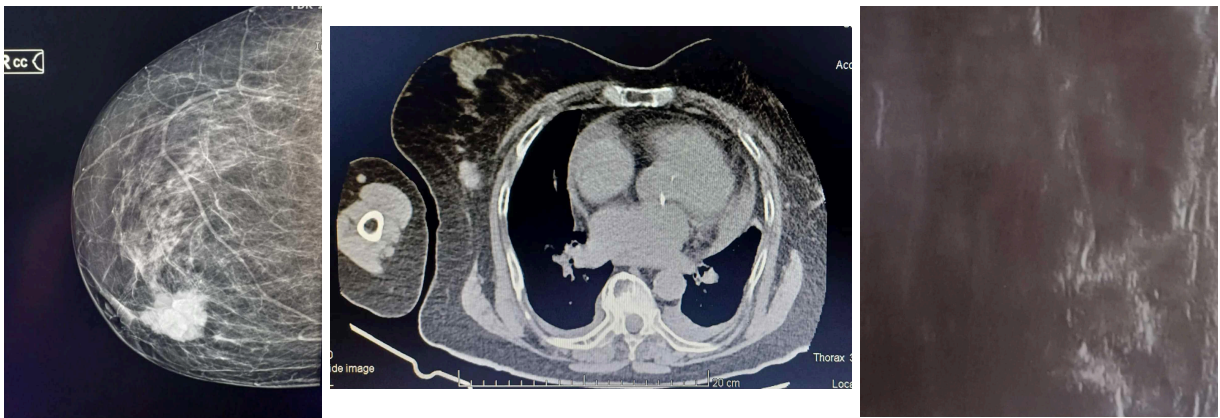
A 78-year-old female patient with comorbidities of epilepsy and chronic heart failure presented with a firm palpable mass above the right nipple, which she noticed on

self-examination. Due to her comorbidities and socioeconomic limitations, the patient was unable to fully care for her health. Upon clinical examination by her general practitioner, a firm, immobile retroareolar mass was confirmed, along with an enlarged right axillary lymph node (approximately the size of a walnut).

The overlying skin was shiny and taut, with areas resembling 'orange peel,' moderate erythema, and nipple retraction. The patient underwent the following laboratory and imaging investigations:

- Complete blood count, ESR, CRP, tumor markers (CA15-3, CEA)
- Chest X-ray
- CT scan
- Breast ultrasound
- Fine-needle aspiration biopsy (FNAB)

Laboratory results, including tumor markers, were within normal limits. Chest radiography revealed cardiomegaly. Mammography showed a retroareolar hyperdense multilobulated mass (Figure 2.a). Ultrasound confirmed a hypoechoic subcutaneous irregular lesion consistent with malignancy (Figure 2.c). CT imaging showed no abnormalities in the brain or skull. Left-sided pleural and pericardial effusions were present, with evidence of cardiomyopathy (Figure 2.b). Histopathological examination revealed a malignant epithelial neoplasm composed of atypical tumor cells with moderate nuclear pleomorphism forming tubular, cribriform, and focally papillary structures. Sparse intratumoral lymphocytic infiltration was noted. Immunohistochemistry showed strong nuclear positivity for estrogen receptors (ER 90%) and weak positivity for progesterone receptors (PR 2%). The final diagnosis was invasive breast carcinoma.



a.

b.

c.

Figure 2. (a). Mammography showed retroareolar hyperdense multilobulated mass; (b.) Thoracic CT showed left-sided pleural and pericardial effusions, with evidence of cardiomegaly; (c.) ultrasound confirmed a hypoechoic subcutaneous irregular lesion.

Discussion

Invasive breast carcinoma remains the most common malignant breast tumor among women worldwide and continues to be a significant public health concern due to its high morbidity and mortality (1,2). Early diagnosis and treatment are crucial for improving outcomes, as prognosis is strongly influenced by tumor biology, stage at presentation, and timely initiation of therapy (3,5). In this case, a 78-year-old female presented with a palpable retroareolar mass, skin retraction, erythema, and a “peau d’orange” appearance—clinical features strongly suggestive of locally advanced breast carcinoma. Diagnosis was established through multimodal imaging and fine-needle aspiration biopsy, confirming invasive ductal carcinoma, the most common histopathologic subtype of invasive breast cancer (3). The tumor demonstrated strong estrogen receptor expression (ER 90%) and weak progesterone receptor positivity (PR 2%), suggesting a hormonally driven subtype. However, low PR expression may correlate with more aggressive behavior and reduced response to endocrine therapy, commonly associated with luminal B biology (5). This highlights the importance of molecular profiling in guiding therapeutic decisions.

A unique aspect of this case is the patient's advanced age, comorbidities, and limited health-seeking behavior, contributing to delayed presentation. Older patients often face diagnostic and therapeutic challenges, including reduced access to screening, limited social support, and higher treatment-related risks (7). These factors frequently result in late-stage presentation and restricted management options, despite evidence that breast cancer incidence remains significant in elderly populations (2,4).

Importantly, due to her socioeconomic circumstances and personal limitations, the patient did not undergo surgical or oncological consultation following biopsy confirmation, and therefore no definitive treatment was initiated. This introduces a critical perspective: timely diagnosis alone is insufficient without access to treatment pathways. The gap between diagnosis and therapy reflects systemic barriers that disproportionately affect elderly individuals, especially those with limited financial, social, or logistical support. Such disparities may influence survival rates independent of tumor biology, underscoring the need for public health strategies aimed at improving healthcare accessibility for vulnerable populations (8,9).

Conclusion

Overall, this case highlights not only the diagnostic value of multimodal imaging and histopathology in suspected breast malignancy but also the real-world challenges in managing elderly patients with limited access to care. It emphasizes the necessity of multidisciplinary coordination and social support interventions to ensure that diagnosis

leads to meaningful treatment and improved outcomes. These findings highlight the need for targeted public health strategies aimed at vulnerable elderly populations, improved screening accessibility, and interventions that address social disparities in cancer care. Ultimately, multidisciplinary coordination and personalized treatment planning remain essential to improving outcomes in older patients with breast malignancies.

References:

1. World Health Organization (WHO). Breast cancer: prevention and control. Geneva: World Health Organization; 2023.
2. Bray F, Ferlay J, Soerjomataram I, Siegel RL, Torre LA, Jemal A. Global cancer statistics 2020: GLOBOCAN estimates of incidence and mortality worldwide for 36 cancers in 185 countries. *CA Cancer J Clin.* 2021;71(3):209–249.
3. Rakha EA, Reis-Filho JS, Baehner F, Dabbs DJ, Decker T, Eusebi V, et al. Breast cancer histologic grading and prognosis. *Breast Cancer Res.* 2010;12(4):207.
4. Harbeck N, Penault-Llorca F, Cortes J, Gnant M, Houssami N, Poortmans P, et al. Breast cancer. *Nat Rev Dis Primers.* 2019;5(1):66.
5. Nelson HD, Zakher B, Cantor A, Fu R, Griffin J, O'Meara ES, et al. Risk factors for breast cancer for women aged 40 to 49 years: a systematic review and meta-analysis. *Ann Intern Med.* 2012;156(9):635–648.
6. Smithuis R, de Bes J, Zeillemaker A. Staging and treatment of breast cancer. *Radiology Assistant.* 2016.
7. Arndt V, Stürmer T, Stegmaier C, Ziegler H, Dhom G, Brenner H. Patient delay and stage of diagnosis among breast cancer patients in Germany -- a population based study. *Br J Cancer.* 2002 Apr 8;86(7):1034-40. doi: 10.1038/sj.bjc.6600209.
8. Bourgeois A, Horrill T, Mollison A, Stringer E, Lambert LK, Stajduhar K. Barriers to cancer treatment for people experiencing socioeconomic disadvantage in high-income countries: a scoping review. *BMC Health Serv Res.* 2024 May 28;24(1):670. doi: 10.1186/s12913-024-11129-2.
9. Yu XQ, O'Connell DL, Gibberd RW, Armstrong BK. Socioeconomic disparities in breast cancer survival: relation to stage at diagnosis, treatment, and race. *BMC Cancer.* 2009; 9:364.